


medartis®

PRECISION IN FIXATION

SURGICAL TECHNIQUE

Ulna Shortening System 2.5



APTUS®
Wrist

Surgical Technique

Ulna Shortening System 2.5

Ulna Shortening with Saw Guide 45°

Example and technique by **Michael Sauerbier, MD, PhD**, Chair; Professor for Plastic Surgery; Department for Plastic, Hand and Reconstructive Surgery, Berufsgenossenschaftliche Unfallklinik Frankfurt am Main, Academic Hospital of the Goethe University Frankfurt am Main, Germany

and

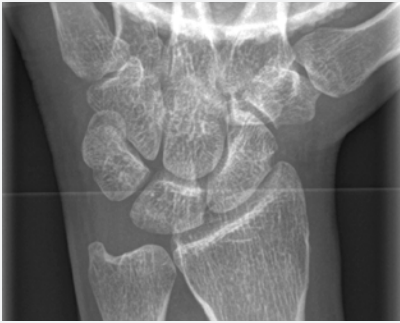
Andrew J. Weiland, Professor of Orthopaedic and Plastic Surgery, Weill Cornell Medical Center and Hospital for Special Surgery (HSS), New York, USA

Indications

- APTUS Ulna Plates are indicated for osteotomies, in particular for the ulna

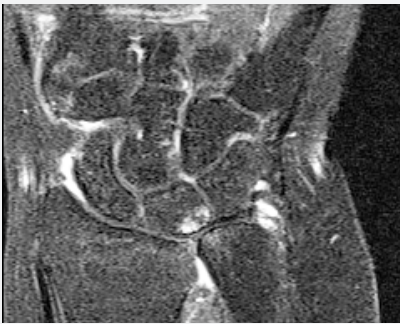Typical Applications

- Refractory ulnar impaction syndrome after unsuccessful wrist arthroscopy, and debridement of the triangular fibrocartilage complex (TFCC), or after a lunotriquetral injury
- Ulnar plus variance of > 2 mm, either congenital or acquired, usually after a malunited distal radius fracture; shortened radius due to premature epiphyseal closure

Preoperative X-rays

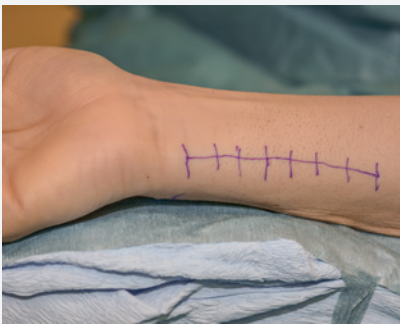
Stress x-ray of the wrist (ball grip) with clear ulnar plus variance of > 2 mm.

An ulnar variance of 2.5 mm leads to a 42% increase of the longitudinal force transmitted through the ulnocarpal joint.



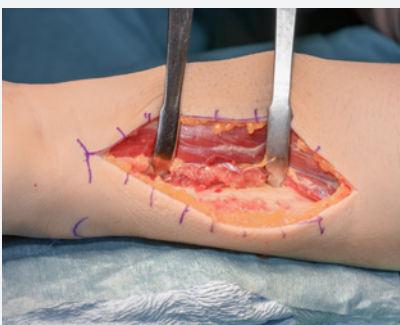
As a result, the compressive stress on the ulnar part of the lunate bone is increased.

This can be confirmed by diagnostic MRI. The scan shows bone marrow edema in the stress zone of the lunate bone. The ulnar impaction syndrome here should not be confused with an altered blood supply to the lunate seen in aseptic necrosis of the lunate bone.

Step 1

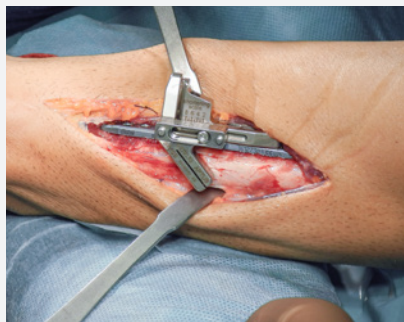Surgery is performed with the patient supine, the arm placed on a hand table and a tourniquet applied to the upper arm.

Skin incision is marked on the ulno volar aspect of the forearm in supination. The 8 cm incision is along the distal third of the ulna, between the tendons of the extensor and flexor carpi ulnaris muscles.


Step 2

The incision is made between the flexor and extensor muscles through the intermuscular septum to ensure good soft tissue coverage. Expose the ulna. Retract the pronator quadratus muscle away from the ulna radially.

Step 3




Carefully incise the periosteum. Position the plate with the instruments as far distal as possible on the volar aspect of the ulna.



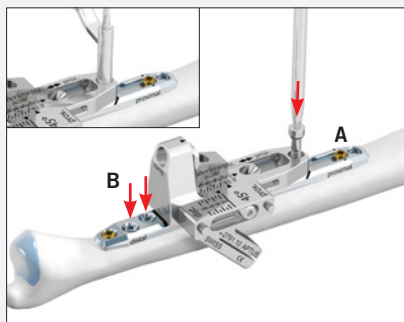
Insert the compression element into the basic element and fix it to the plate using the integrated screw. Tighten the screw with the screwdriver.

Mount the saw guide 45° on the basic element.



Insert a gold cortical screw into the most distal plate hole (A).

Using the opposite side of the drill guide, pre-drill a hole through the proximal end of the oblong hole (B).

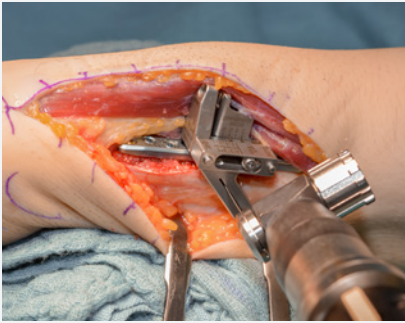


Insert a gold cortical screw into the oblong hole (A).


Pre-drill the two remaining distal plate holes and insert blue TriLock screws (B).

Pre-drill through the proximal end of the basic element using the drill guide and insert the temporary tension bolt.

Step 4



Perform the first cut of the oblique osteotomy with the oscillating saw.



Notice:

The saw guide is placed in the starting position. The saw blade must have the following dimensions:


Thickness: 0.4 mm

Width: ~10 mm

Length: ~30 mm

Expert tip:

Cool the saw blade with Ringer's solution during the osteotomy.

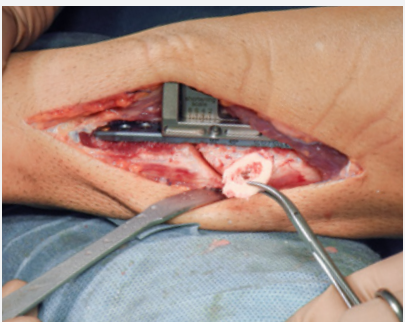

Reposition the saw guide according to the amount of shortening preferred and perform the second cut.

Expert tip:

Ensure that the cortical bone volar to the plate is completely cut over the full width of the ulna.

Step 5

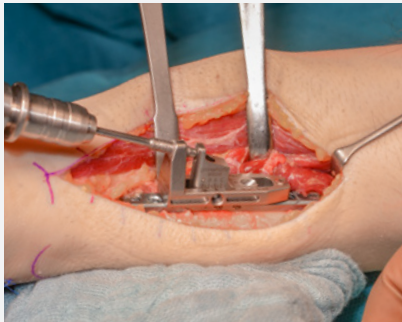


Loosen the integrated screw and remove the saw guide. Remove the bone wafer with Kocher forceps or tweezers. If necessary, use the scalpel to release the wafer.

Notice:

Ensure that no bony residues or bone protrusions are left in the osteotomy gap, as these would prevent complete compression.

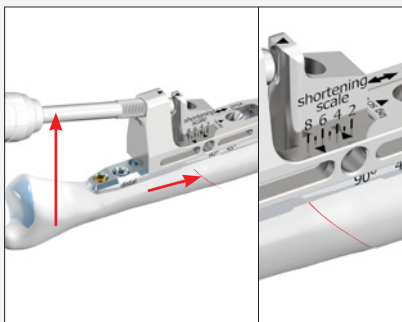
Step 6



Slightly loosen the temporary tension bolt and the gold screw in the proximal oblong hole (1/2 to max. 3/4 turn). Insert the compression spindle into the basic element.

Notice:

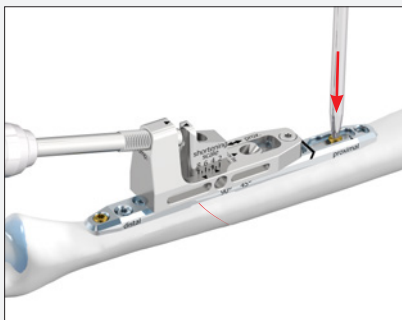
To avoid jamming of the compression spindle it must be lubricated before it is inserted into the basic element, see Instructions for Use for Medartis APTUS Plates, Screws and Instruments (chapter «Product Care»).




Double-check the shortening length on the «shortening scale» to avoid over-compression.

Over-compression can result in slight displacement of the osteotomy. Use of a clamp can prevent this.

Step 7

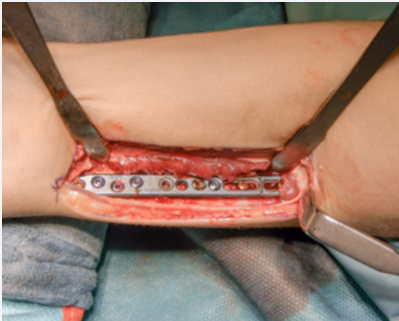


Re-tighten the gold cortical screw in the most proximal oblong hole.



Using the drill guide, pre-drill through the specified hole in the basic element and insert a set screw perpendicular to the osteotomy gap. This provides additional interfragmentary stability.

Step 8

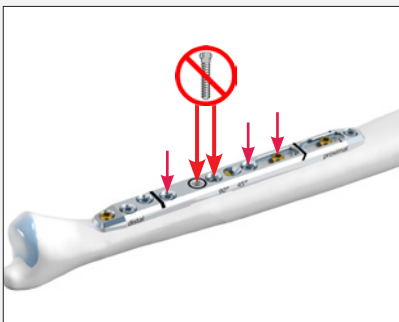


Fluoroscopic control in the anteroposterior and lateral planes to assess the position of the plate and screws and the compression on the osteotomy gap. Also check the stability of the distal radioulnar joint.

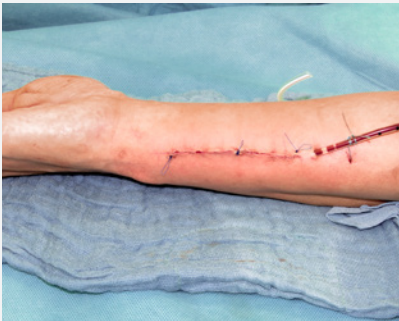Insert a gold cortical screw in the distal oblong hole and TriLock screws in the remaining plate holes. In the 45° technique, the plate hole marked with the black ring and the hole proximal to this hole remain empty.

Expert tip:

During screw insertion, ensure that the screws are chosen 1–2 mm shorter than measured.



Step 9

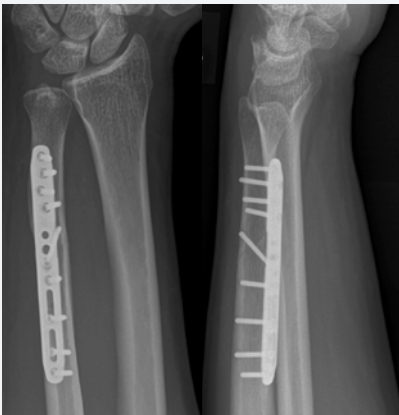

Release the tourniquet and restore blood flow, irrigate the site and perform hemostasis. Subcutaneous sutures are followed by an intracutaneous continuous suture with monofilament non-absorbable 4–0 suture.

Apply a sterile, circular compression bandage and a short ulno volar splint.

Postoperative management:
Sutures are removed in 2 weeks and a volar forearm orthoplast splint is used for an additional 3 weeks.

Postoperative X-ray



The postoperative X-ray of the wrist (6 months after the operation) shows the anatomically correct position of the distal radioulnar joint, correct position of the plate and correct interfragmentary compression.

For further information regarding the APTUS product line visit:
www.medartis.com/products

WRIST-10010026_v0 / © 2017-08, Medartis AG, Switzerland. All technical data subject to alteration.

Caution: The devices are restricted to sale only by or on the order of a physician or a hospital.

MANUFACTURER & HEADQUARTERS

Medartis AG | Hochbergerstrasse 60E | 4057 Basel/Switzerland

P +41 61 633 34 34 | F +41 61 633 34 00 | www.medartis.com

USA

Medartis Inc. | 224 Valley Creek Boulevard, Suite 100 | Exton, PA 19341

P +1 610 961 6101 | Toll free 877 406 BONE (2663) | F +1 610 644 2200

SUBSIDIARIES

Australia | Austria | France | Germany | Mexico | New Zealand | Poland | UK | USA

For detailed information regarding our subsidiaries and distributors, please visit www.medartis.com

