

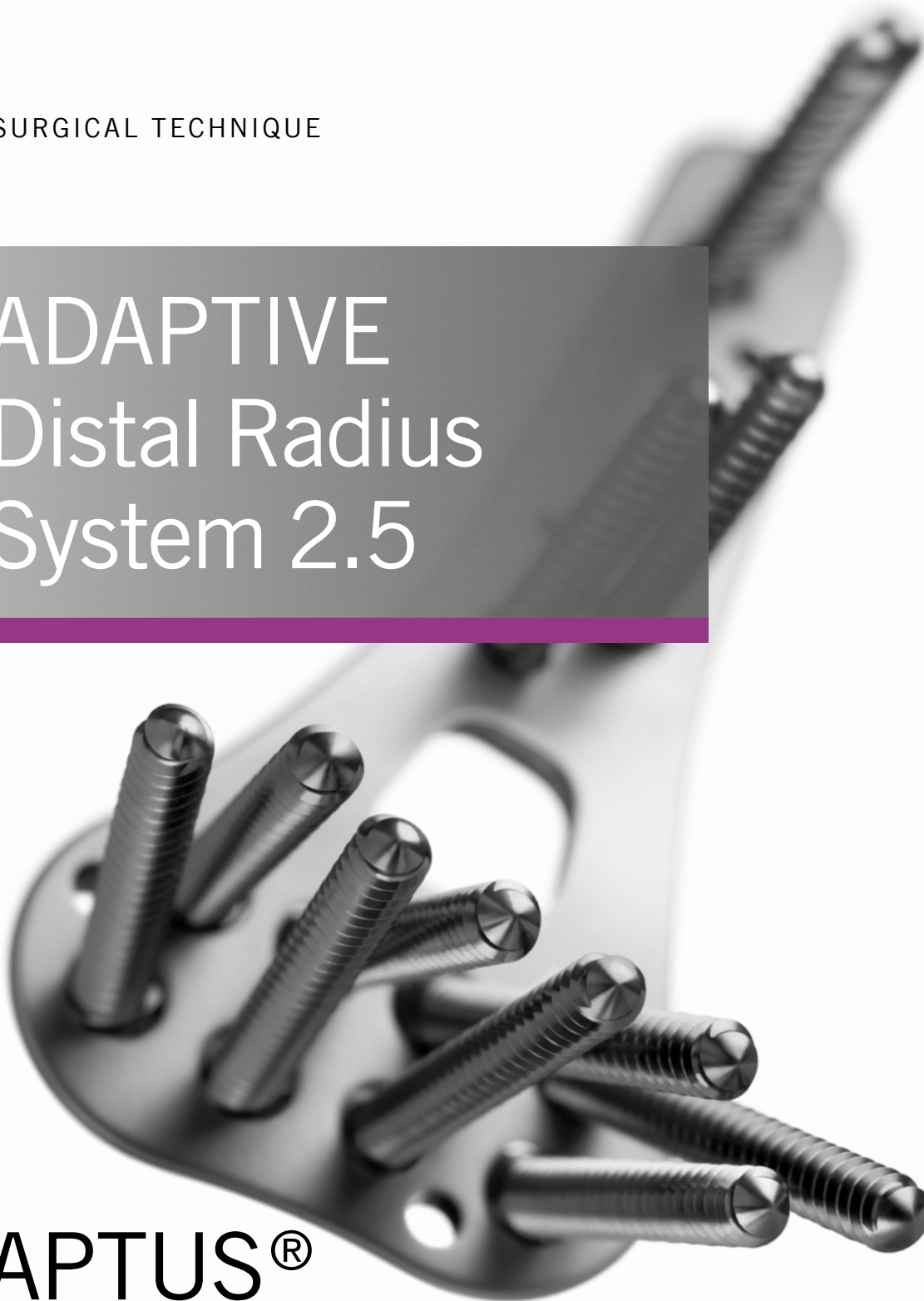medartis®

PRECISION IN FIXATION

SURGICAL TECHNIQUE

ADAPTIVE Distal Radius System 2.5

APTUS®
Wrist



LITERATURE

1. Krimmer, H., Pessenlehner, C., Haßelbacher, K., Meier, M., Roth, F., and Meier, R. Palmar fixed angle plating systems for instable distal radius fractures [Palmare winkelstabile Plattenosteosynthese der instabilen distalen Radiusfraktur] Unfallchirurg, 107[6], 460-467. 2004.
2. Mehling, I., Meier, M., Schloer, U., and Krimmer, H. Multidirectional Palmar Fixed-Angle Plate Fixation for Unstable Distal Radius Fracture [Multidirektionale winkelstabile Versorgung der instabilen distalen Radiusfraktur] Handchir.Mikrochir.Plast.Chir, 39[1], 29-33. 2007.
3. Moser, V. L., Pessenlehner, C., Meier, M., and Krimmer, H. Anterior Fixed Angle Plate Fixation of Unstable Distal Radius Fractures [Palmare winkelstabile Plattenosteosynthese der instabilen distalen Radiusfraktur] Operat.Orthop.Traumatol., 16[4], 380-396. 2004.
4. Jakubietz, R. G., Gruenert, J. G., Kloss, D. F., Schindele, S., and Jakubietz, M. G. A Randomised Clinical Study Comparing Palmar and Dorsal Fixed-Angle Plates for the Internal Fixation of AO C-Type Fractures of the Distal Radius in the Elderly Journal of Hand Surgery, European Volume 33[5], 600-604. 2008.
5. Figl, M., Weninger, P., Liska, M., Hofbauer, M., and Leixnering, M. Volar fixed-angle plate osteosynthesis of unstable distal radius fractures: 12 months results Arch.Orthop.Trauma Surg., 129[5], 661-669. 2009.
6. Weninger, P., Schueller, M., Drobetz, H., Jamek, M., Redl, H., and Tschegg, E. Influence of an Additional Locking Screw on Fracture Reduction After Volar Fixed-Angle Plating – Introduction of the “Protection Screw” in an Extra-Articular Distal Radius Fracture Model Journal of Trauma - Injury, Infection, and Critical Care, 67[4], 746-751. 2009.
7. Figl, M., Weninger, P., Jurkowitsch, J., Hofbauer, M., Schauer, J., and Leixnering, M. Unstable Distal Radius Fractures in the Elderly Patient – Volar Fixed-Angle Plate Osteosynthesis Prevents Secondary Loss of Reduction Journal of Trauma - Injury, Infection, and Critical Care, 68[4], 992-998. 2010.
8. Sonderegger, J., Schindele, S., Rau, M., and Gruenert, J. G. Palmar multidirectional fixed-angle plate fixation in distal radius fractures: do intraarticular fractures have a worse outcome than extraarticular fractures? Arch.Orthop.Trauma Surg., 2010.
9. Richter, R., Konul, E., and Krimmer, H. Strategy of early corrective osteotomy [Strategie der Radiusfrühkorrektur] Obere Extremität, 5[2], 92-97. 2010.
10. Haefeli, M., Stober, R., Plaass, C., Jenzer, A., and Steiger, R. First experience with a dorsal plate in modern design for the treatment of distal radius fractures Journal of Hand Surgery, European Volume 35E[S1], A-0461. 2010.

A close-up, black and white photograph of a threaded metal rod, likely a surgical drill bit, running diagonally across the frame. The threads are clearly visible and the lighting creates a sense of depth and texture.

ADAPTIVE Distal Radius System 2.5

CONTENTS

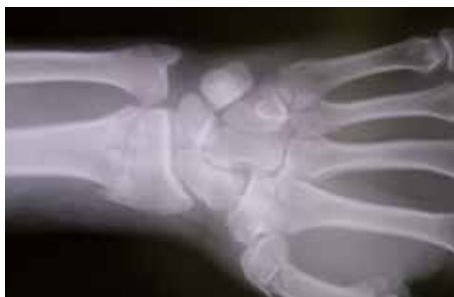2	Literature
4-6	Surgical Technique
7-9	Surgical Technique with Drill Guide Block
10	Correct Use of TriLock Locking Technology
11	Addresses

Surgical Technique

Fixation of an intra-articular extension fracture with dorsal comminuted zone with the multidirectional, angular stable ADAPTIVE TriLock Distal Radius Plate, volar

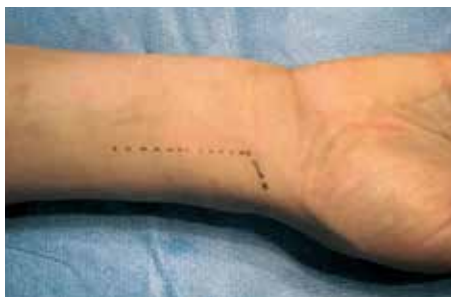Example and technique by Dr. Weiland, Hospital for Special Surgery, New York, USA

Clinical Case



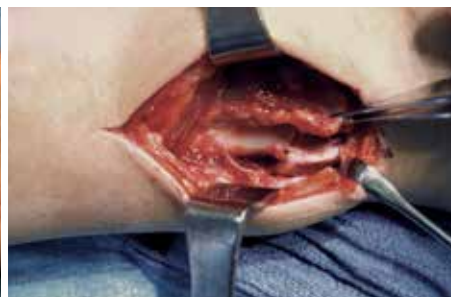STEP 1

Preoperative X-ray.



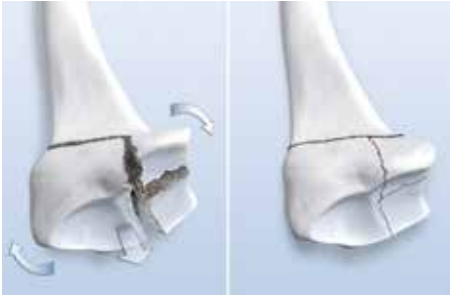STEP 2

A 5 cm incision centered over the distal aspect of the flexor carpi radialis (FCR) with an incision towards the radial styloid is made and carried down to skin and subcutaneous tissue. Bipolar electrocoagulation is used to control bleeding in the area.

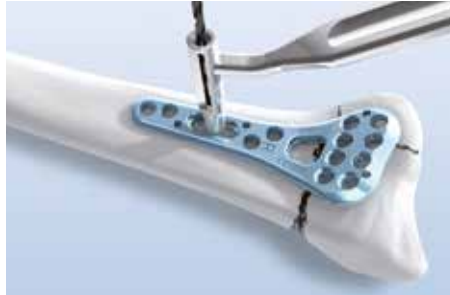

STEP 3

Make an incision on the radial aspect of the FCR tendon sheath. Preserve the volar branch of the radial artery. Blunt dissection and retraction medially of the FCR and the underlying flexor tendons is carried out including the flexor pollicis longus (FPL). The radial artery is protected. The pronator quadratus (PQ) is dissected sharply from the radius. The brachio-radialis tendon is sharply elevated from the distal radius and radial styloid. The PQ dissection is continued medially, elevating the PQ from the distal aspect of the radius to the level of the joint. The fracture site is cleaned and inspected.

**STEP 4**

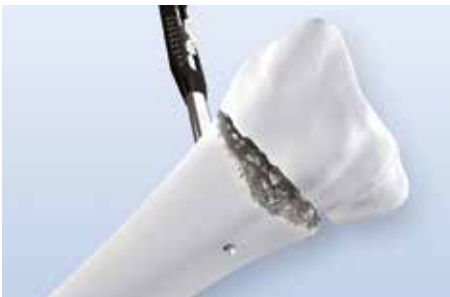With the brachio-radialis removed, the fracture can be reduced more easily. A rolled towel is placed beneath the dorsum of the hand to position the wrist in slight flexion. The plate is then applied using a small elevator to palpate the distal aspect of the radius.

**STEP 5**

After positioning the plate, the drill guide (A-2722) and the twist drill (A-3713, A-3723, A-3733) are placed in the longitudinal oriented slot in order to allow for further adjustment of the plate if necessary.

**STEP 6A**

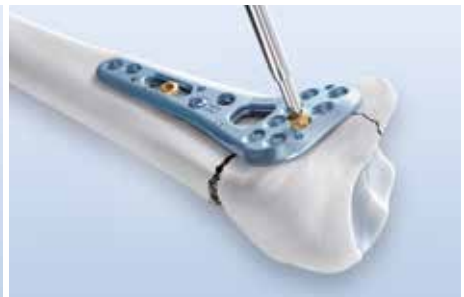Screw length is determined using the depth gauge (A-2730).

**STEP 6B**

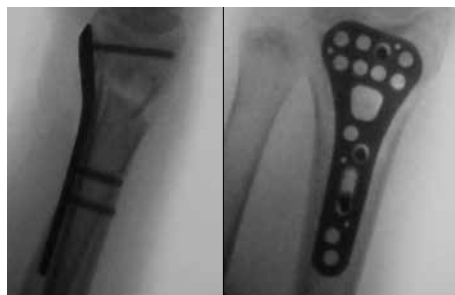Dorsal view of the caliper needle on the far cortex.

**STEP 7**

A gold cortical screw is inserted into the longitudinal oriented slot for prefixation.

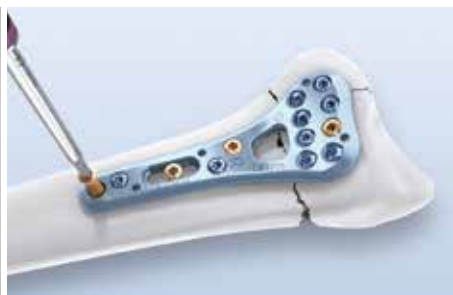**STEP 8**

After a blue TriLock screw has been inserted proximal to the fracture site, a gold cortical screw is inserted in the distal row in order to secure the distal fragment to the plate.



STEP 9

Intraoperative fluoroscopy assesses the position of the plate and confirms that it is satisfactory.

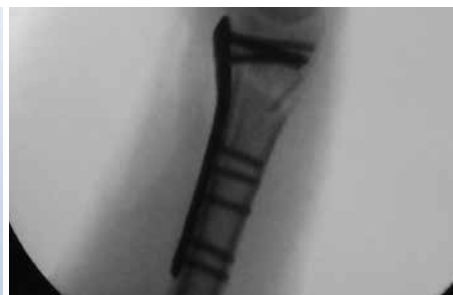

STEP 10

Once the plate position has been confirmed, additional screws are inserted; TriLock screws are used in the two distal rows of the plate. Complete the fixation of the plate shaft with screws of which at least 1 should be a TriLock screw.

Note:

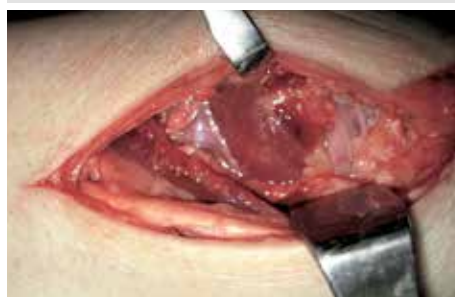For ideal results, place at least 3 blue TriLock screws in the most distal row and 2 blue TriLock screws in the second distal row.



STEP 11

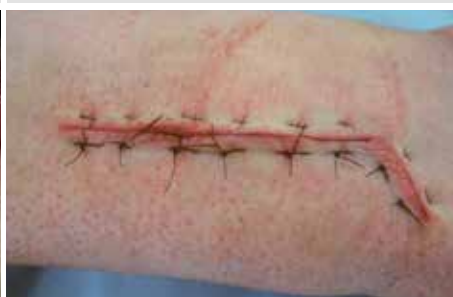Final intraoperative X-rays are obtained in the anterior-posterior, lateral and oblique projections angling the X-ray tube to be parallel to the 11° volar tilt and also the 21° radial inclination to ascertain that there are no screws in the joint.

(Reference: Boyer et. al., THS29A: 116-122, 2004)



STEP 12

Following irrigation, the PQ is reattached with several 3-0 braided dacron sutures.



STEP 13

The pneumatic cuff is then deflated. Hemostasis is obtained with bipolar electrical coagulation and the wound closed with interrupted 4-0 nylon sutures.

Note:

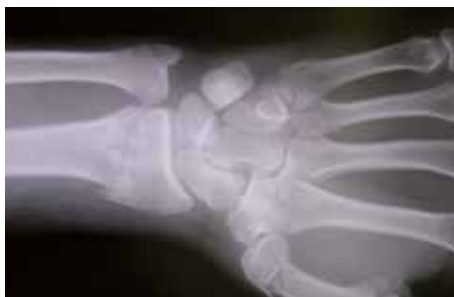It should be mentioned that after reduction and fixation, the distal radial ulnar joint is assessed for stability. A sterile dressing is then applied and a volar plast splint is fashioned.

Surgical Technique with Drill Guide Block

Fixation of an intra-articular extension fracture with dorsal comminuted zone with the multidirectional, angular stable ADAPTIVE TriLock Distal Radius Plate, volar

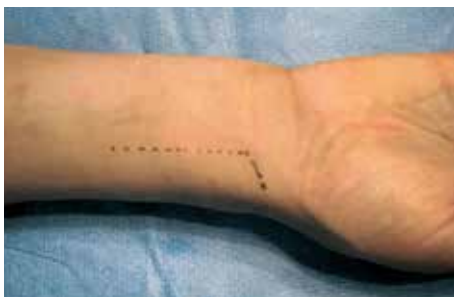Example and technique by Dr. Weiland, Hospital for Special Surgery, New York, USA

Clinical Case



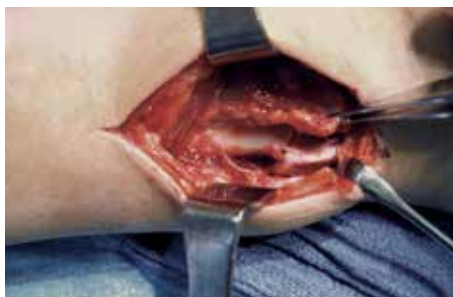STEP 1

Preoperative X-ray.



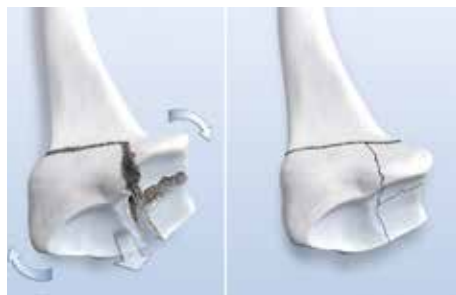STEP 2

A 5 cm incision centered over the distal aspect of the flexor carpi radialis (FCR) with an incision towards the radial styloid is made and carried down to skin and subcutaneous tissue. Bipolar electrocoagulation is used to control bleeding in the area.



STEP 3

Make an incision on the radial aspect of the FCR tendon sheath. Preserve the volar branch of the radial artery. Blunt dissection and retraction medially of the FCR and the underlying flexor tendons is carried out including the flexor pollicis longus (FPL). The radial artery is protected. The pronator quadratus (PQ) is dissected sharply from the radius. The brachio-radialis tendon is sharply elevated from the distal radius and radial styloid. The PQ dissection is continued medially, elevating the PQ from the distal aspect of the radius to the level of the joint. The fracture site is cleaned and inspected.



STEP 4

With the brachio-radialis removed, the fracture can be reduced more easily. A rolled towel is placed beneath the dorsum of the hand to position the wrist in slight flexion. The plate is then applied using a small elevator to palpate the distal aspect of the radius.



STEP 5

Place the plate with the already attached fixed angled drill guide block centrally to the longitudinal axis of the radius. The distal aspect of the plate is positioned as close as possible to the watershed line (approximately 1 cm proximal to the radio carpal joint (RCJ)).

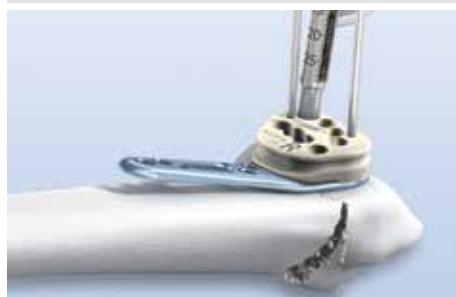

STEP 6

Once the final position has been determined, K-wires are inserted into the holes provided to assure correct alignment relative to the RCJ and the distal radio ulnar joint (DRUJ).

Note:

Check K-wire positions under fluoroscopy.



STEP 7A

Starting with the most ulnar hole, the first row of screws is inserted. The first screw is a gold cortical screw, the remaining are blue TriLock screws. Once this is accomplished, a second row of blue TriLock screws is inserted.

Note:

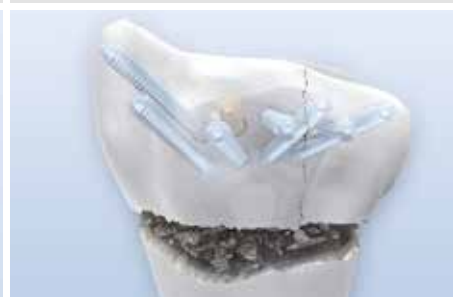Each screw hole has to be drilled, measured and the screw inserted individually. After fixing the first screw, remove the K-wire from the most ulnar hole.

For ideal results, place at least 3 blue TriLock screws in the most distal row and 2 blue TriLock screws in the second distal row.



STEP 7B

The depth of the hole (= screw length) can be determined by reading the scale on the drill guide or by using the standard depth gauge (A-2730). If the standard gauge is used, it is inserted through the fixed angled drill guide block.



STEP 8

Shown above is the ideal subchondral positioning of the TriLock screws in the distal aspect of the plate. The proximal row of screws is used for support of the dorsal rim. The distal screw row is used for support of the central portion of the articular surface.



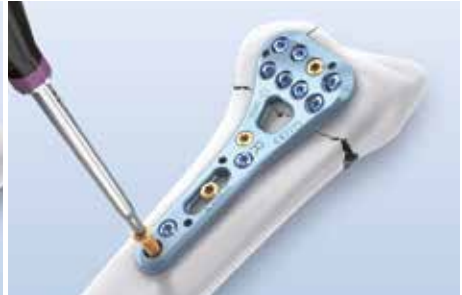STEP 9

Both the remaining K-wire and the fixed angled drill guide block are removed. The distal fragment is reduced by aligning the proximal end of the plate shaft.



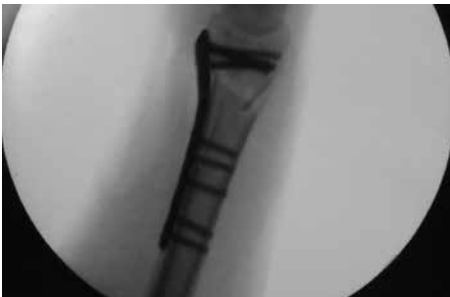STEP 10

Continue fixation by placing a gold cortical screw in the longitudinal oriented slot. Adjustment of the distal aspect of the radius can now be performed.



STEP 11

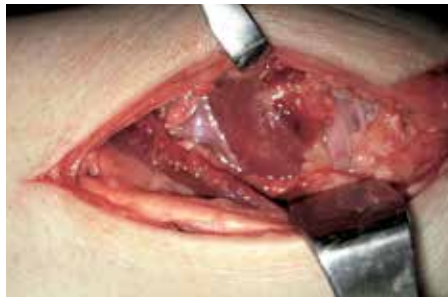Complete the fixation of the plate shaft with screws of which at least 1 should be a TriLock screw.



STEP 12

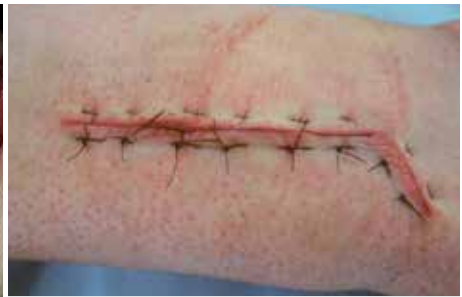Final intraoperative X-rays are obtained in the anterior-posterior, lateral and oblique projections angling the X-ray tube to be parallel to the 11° volar tilt and also the 21° radial inclination to ascertain that there are no screws in the joint.

(Reference: Boyer et. al., THS29A: 116-122, 2004)



STEP 13

Following irrigation, the PQ is reattached with several 3-0 braided dacron sutures.



STEP 14

The pneumatic cuff is then deflated. Hemostasis is obtained with bipolar electrical coagulation and the wound closed with interrupted 4-0 nylon sutures.

Note:

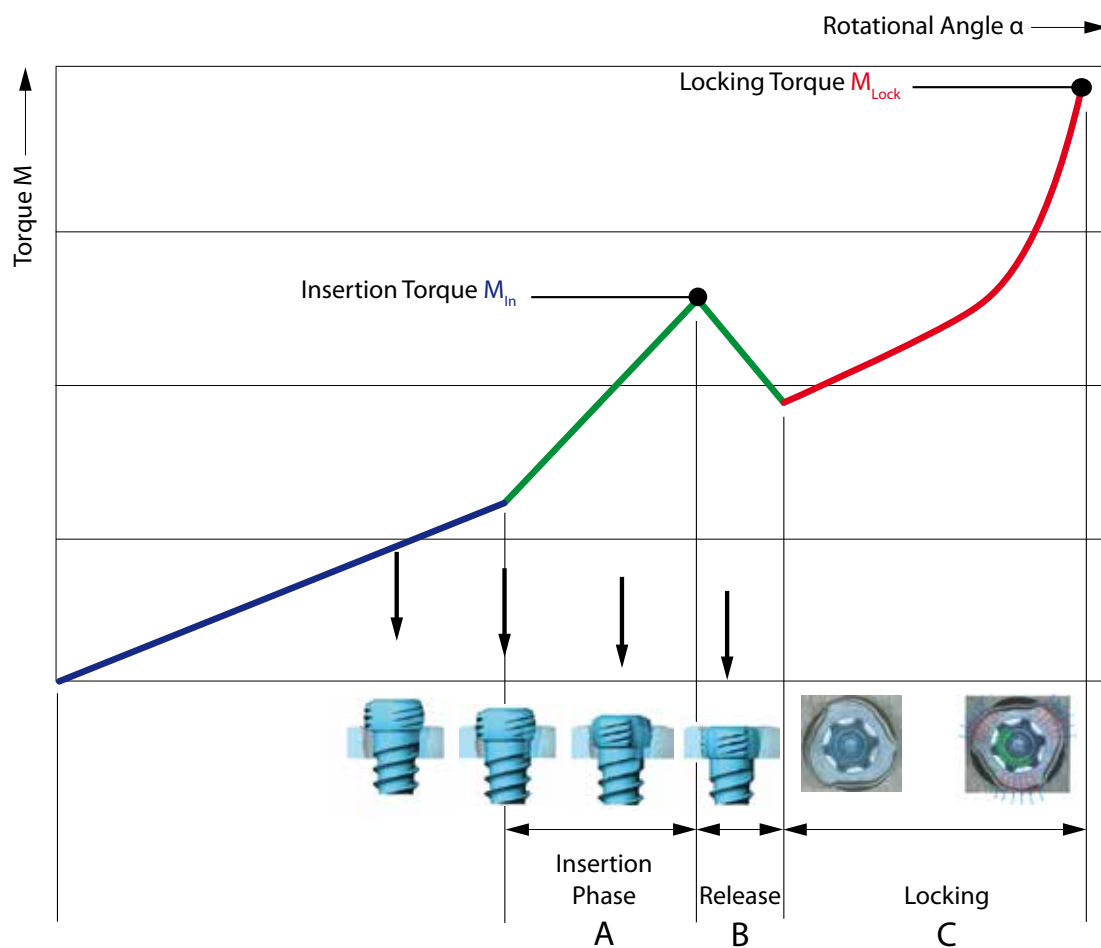
It should be mentioned that after reduction and fixation, the distal radial ulnar joint is assessed for stability. A sterile dressing is then applied and a volar plast splint is fashioned.

CORRECT APPLICATION OF THE TRILOCK LOCKING TECHNOLOGY

The screw is inserted through the plate hole into a pre-drilled canal in the bone. An increase of the tightening torque will be felt as soon as the screw head gets in contact with the plate surface.

This indicates the start of the “Insertion Phase” as the screw head starts entering the locking zone of the plate (section “A” in the diagram). Afterwards, a drop of the tightening torque occurs (section “B” in the diagram). Finally the actual locking is initiated (section “C” in the diagram) as a friction connection is established between screw and plate when tightening firmly.

The torque applied during fastening of the screw is decisive for the quality of the locking as described in section “C” of the diagram.



CORRECT LOCKING ($\pm 15^\circ$) OF THE TRILOCK SCREWS IN THE PLATE

Visual inspection of the screw head projection provides an indicator of correct locking. Correct locking has occurred only when the screw head has locked flush with the plate surface (figures 1+3). However, if the screw head can still be seen or felt (figures 2+4), the screw head has not completely entered the plate and reached the locking position. In this case the screw has to be retightened to obtain full penetration and proper locking.

Do not overtighten the screw, otherwise the locking function cannot be guaranteed anymore.

Correct: LOCKED




Figure 1

Incorrect: UNLOCKED




Figure 2

Correct: LOCKED




Figure 3

Incorrect: UNLOCKED

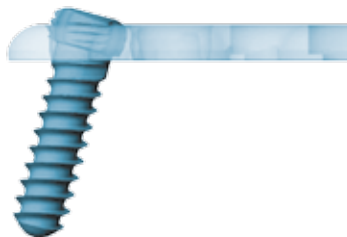


Figure 4

WRIST-01010006_v3 / © 06.2013, Medartis AG, Switzerland. All technical data subject to alteration.

HEADQUARTERS

Medartis AG | Hochbergerstrasse 60E | 4057 Basel/Switzerland

P +41 61 633 34 34 | F +41 61 633 34 00 | www.medartis.com

USA

Medartis Inc. | 224 Valley Creek Blvd., Ste 100 | Exton, PA 19341

P +1 610 961 6101 | Toll free 877 406 BONE (2663) | F +1 610 644 2200

SUBSIDIARIES

Australia | Austria | France | Germany | Mexico | New Zealand | Poland | UK | USA

For detailed information regarding our subsidiaries and distributors, please visit www.medartis.com