

# CASE STUDY



## The use of NX Nail for fixation of a displaced fourth metacarpal shaft fracture

### The Surgeon

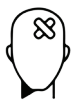#### Dr. Raymond K. Wurapa, MD

Orthopaedic Hand Surgeon at Orthopaedic ONE, Columbus Ohio. Specialist in hand, wrist and upper extremity. Fellow of Philadelphia Hand to Shoulder Centre, Thomas Jefferson University, Pennsylvania.

#### Overview

A 25-year-old male presented to the local emergency room for treatment of a painful and swollen right hand after a fall. Upon review by Dr. Wurapa six days later, radiographs revealed a displaced shaft fracture of the fourth metacarpal. Incidentally, there was a small plate present on the fifth metacarpal in the same hand from a prior remote injury. With the patient adamant to avoid the painful and prolonged recovery he had previously experienced, Dr. Wurapa opted for a 3.5mm diameter, 50mm length NX Nail to provide definitive fixation. Six days post-operatively the patient had good hand motion and was given a splint to aid in his return to work. By eight weeks, he reported no pain or functional limitations. In this case, Dr. Wurapa was able to treat a young patient who was keen to return to work with a superior alternative to plate fixation.

### The Case



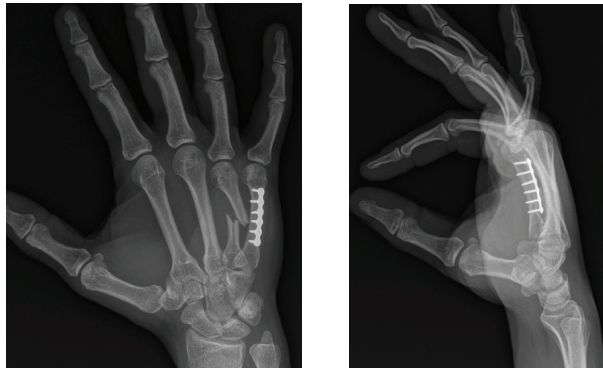
#### Patient Profile

A 25-year-old male presented to the local emergency room for treatment of a painful and swollen right hand after a fall. Radiographs revealed a fractured metacarpal, initial treatment consisted of splint application and referral to Dr. Wurapa for review.



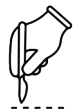### Clinical Findings

The patient presented to Dr. Wurapa six days after he sustained the injury to his dominant right hand. Upon examination, he had pain and swelling from what was revealed on X-ray to be a displaced shaft fracture of the fourth metacarpal. Incidentally, the patient previously sustained a fifth metacarpal fracture some years earlier for which he underwent ORIF with plate fixation (see below). Remarkably, the plate was not disrupted by the fall.



### Pre-operative Assessment

When reviewing treatment options, the patient recalled a harrowing experience from his prior metacarpal injury where he suffered severe post-operative pain and stiffness, prolonging his recovery and ability to regain function and return to work. Adamant to avoid that experience again, the decision was made to treat the fourth metacarpal shaft fracture with an NX Nail from Field Orthopaedics. Several days later he successfully underwent minimally invasive surgery with open reduction internal fixation (ORIF).



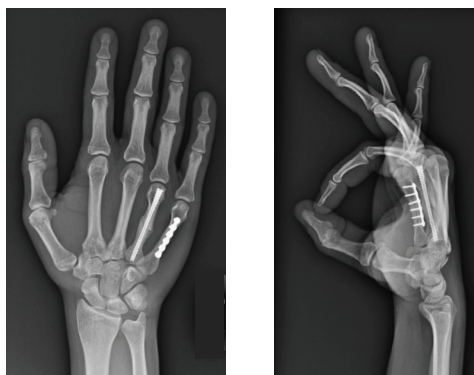
### Surgical Treatment

Under a regional block anaesthesia with light sedation, the arm was prepped and draped per routine. The extremity was exsanguinated, and upper arm tourniquet raised to 200mm Hg.

Under mini C-arm fluoroscopy, the NX Nail depth gauge was used to identify the 3.5mm diameter nail size as ideal. A guidewire from the 3.5mm set was placed retrograde under power from the fourth metacarpal head proximally. The entry point was the dorsal third midline position of the metacarpal head to minimize functional articular disruption. The guidewire was advanced to the proposed depth of the nail within the fourth metacarpal.

A 5mm longitudinal skin incision was made above and below the guidewire. This allowed introduction of the depth gauge to determine a 50mm implant length. The guidewire was then advanced proximally across the fourth carpometacarpal (CMC) joint under power to avoid inadvertent extraction during the remainder of the case. The cannulated drill was passed over the guidewire with required depth confirmed under fluoroscopy. A 3.5mm diameter, 50mm length NX Nail was then advanced by hand over the guidewire and seated into place. Care was taken with final seating of the implant to verify clinical alignment of fourth digit and reduction at the fracture site.

The guidewire was extracted, final imaging obtained, and the wound closed with a 5-0 prolene suture. A soft dressing was applied with no splint.

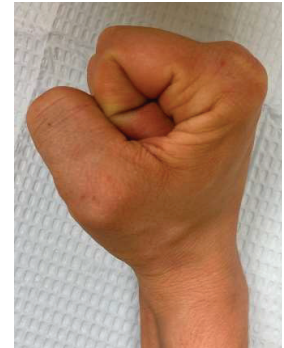
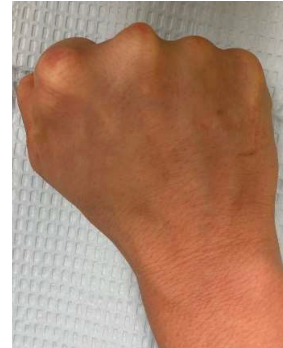
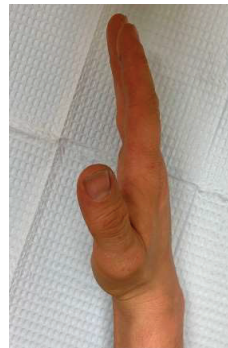
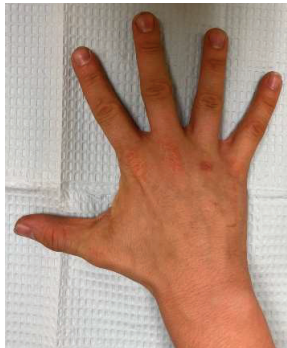
### Post-operative Treatment

The patient was reviewed by Dr. Wurapa six days post-operatively, at which time he had good hand motion. As he was eager to return to work, an orthoplast hand based splint was fabricated in therapy for use only at his physical work position until such time that he felt fully comfortable without it. He was instructed in a home exercise regimen to further mobilize his hand, and quickly transitioned back to full duty at work while weaning his splint use.

By eight weeks post-operatively, the patient reported no pain or functional limitations at home or work. He also had no residual oedema or induration with full painless digital range of motion.



### Conclusion

In this case, Dr. Wurapa was able to treat an unstable metacarpal shaft fracture in a young patient who was keen to regain full function of his hand and return to work as soon as possible. The patient had previously had a poor recovery experience with plate fixation in the same hand. Dr. Wurapa was able to avoid the shortcomings of plate fixation with the intramedullary NX Nail. Designed to maintain length, restore version and control angulation, the NX Nail provides rigid fracture fixation, facilitating rapid return to function with restored native biomechanics.<sup>1</sup> Manufactured from titanium alloy, the NX Nail is strong and simple to use. In this case, it also provided a superior post-operative outcome compared to prior plate fixation, with which he experienced a painful and prolonged recovery.

### References

1. Field Orthopaedics. (2022). NX Nail Design Rationale. Brisbane, Australia: Field Orthopaedics.



#### MANUFACTURER:

Field Orthopaedics Pty. Ltd.  
30 Florence St,  
Teneriffe QLD 4005 Australia  
sales@fieldorthopaedics.com  
[www.fieldorthopaedics.com](http://www.fieldorthopaedics.com)

#### DISTRIBUTED BY:

Medartis Inc.  
1195 Polk Drive  
Warsaw, IN 46582 USA  
574-376-2404  
[medartisusa.com](http://medartisusa.com)